Otoskopische Befunde

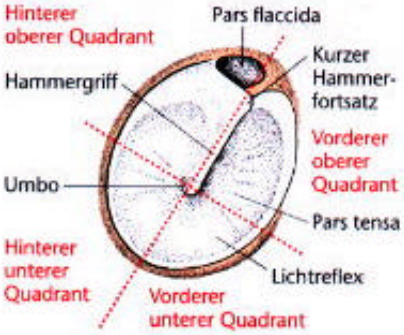

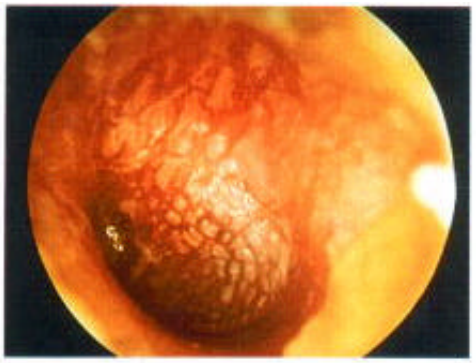

li: Normalbefund
re.o.: akute Otitis M.
re.u.: Paukenröhrchen

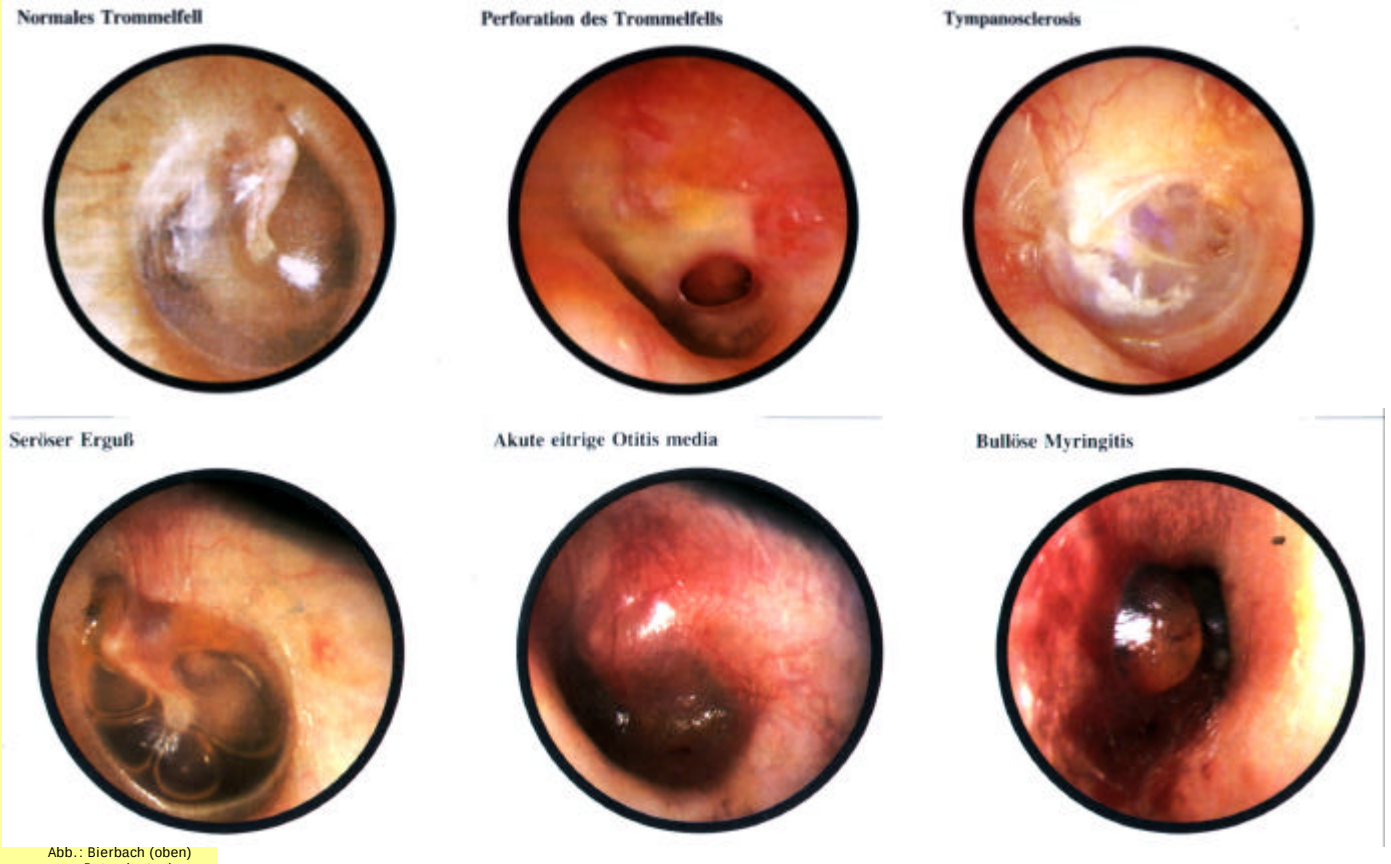

Abb.: Bierbach (oben)
Bates (unten)